

Ridge Widening and Immediate Implant Placement
Dr. Ahmed H. Ayoub . President of ESOI
(Egyptian Osciety of oral implantology)

A Case Report

Alveolar atrophy is a major problem that has limited the use of endosseous implants since their introduction. When an anterior tooth in the mandible is lost, often as a result of trauma or endodontic complications, the labial wall of the alveolar socket resorbs rapidly and the residual ridge actually consists of the previous palatal wall. Therefore, the alveolar ridge is predominantly reduced in the horizontal dimension, and immediate implant placement with routine techniques is not possible because of the discrepancy between the thickness of the ridge and the diameter of the implant. Although numerous procedures have been devised to augment the alveolar crest with autogenous bone grafting, such as the ribs and iliac crest, sometimes in conjunction with a barrier membrane, a risk of dehiscence and infections of the mucosa may jeopardize the graft. Furthermore, a two-stage approach to implant placement is generally advocated, lengthening treatment time and increasing cost. In 1992, Simion et al introduced a split-crest-bone manipulation technique. The purpose of this technique was to create self-spacemaking defects by splitting the atrophic crests into two parts with a longitudinal greenstick fracture and placing the implant between them, which is also an effective technique for severely thin alveolar bone. This is advocated when a standard osteotomy technique in which a crest width .4 mm is recommended cannot be applied. Various types of implants have been used within the ridge widening procedure. Because the taper-shaped implants (Core expansive implant Microdent system) are tapped into position similarly to the driving of a wedge, it is considered to be appropriate for this procedure.

In 1996 Dr. Joaquin Garcia introduced the use of non traumatic be expanders technique in which he used a tapered shape threaded expanders to create enough gap between the splited 2 parts of the atrophic crests to allow a space for implant placement

The present study reports a case of severe mandibular alveolar atrophy during placement of an immediate taper-shaped implant associated with a ridge widening procedure (RWP) using non traumatic expanders.

MATERIALS AND METHODS.

57-year-old woman was referred for prosthetic treatment associated with implant placement. Clinical examination showed an edentulous margin with obvious labial and buccal bone resorption (picture 1) (Lekholm and Zarb's class D atrophy). The radiographic appearance indicated an adequate bone height for implant placement, except that the tomogram view of the anterior mandible region revealed knife-edge morphology. For the purpose of placing the implant with an conical abutment that assists fixed bridge support, four microdent implant_were planned to be placed in the anterior segrment of the mandible and 2 in premolar areas.

Surgical Procedure.

For the prosthetic treatment associated with the implant placement, 6 microdent implant system was prepared.

After appropriate sedation (diazepam, 5 mg; intravenous injection), an incision was made on the crest of the ridge of the bilateral premolar regions slightly toward the lingual aspect . In addition, mesial and distal vertical incisions were extended in the buccal direction for the purpose of flap relief (picture 2). Using a periosteal elevator,

mucoperiosteal flaps were buccally elevated sufficient to visualize the alveolar ridge anatomy. After this, the bone crests revealed that the ridge width was approximately 2 mm in diameter and the buccal aspect had a concave form. A piezo surgery is used carefully to create a channel along the crest of the bone (bone slitting). The channels were extended to a depth of 8 to 10 mm to reduce the occurrence of cortical plate fracture in the subsequent procedures. After cortical plate separation (picture 3), the first yellow expander was inserted to its full length. expander left in place for 30 seconds for bone remodeling

Then the expander was removed and the 2nd red expander was inserted in the bone to the length of 14 mm and left in position (picture 4) for 30 seconds then removed

Then the blue one was inserted to the length of 14 mm and left in position for 30 seconds

By the use of 4 expander kits , a 4 osteotomy sites were prepared with the same way the same time by placing same size expander in the 4 osteotomy then removing all of it and placing the bigger size. the cortical plates were further widened to approximately 4 mm (picture 5). The final depth and orientation of the prepared sites were then checked by inserting the appropriate trial-fit gauge. Also 2 osteotomy sites were prepared in the premolar area using also expansion technique (picture 6). After saline irrigation, the implant microdent system fixtures (length, 12 mm; diameter, 3.8 mm) were placed and driven into their final fully seated positions(picture 7). Releasing incisions in the periosteum at the base of the flap were made to enhance the elasticity of the flap. Closure was carried out by using vertical mattress sutures.

Stage II surgery was scheduled 3 months after the implantation. Complete healing of the defects had taken place, and the fixtures were covered by regenerated bone (picture 8). After the soft tissue was restored by placement of a healing abutment, a conical abutments was attached to the implant fixture. For the final prosthesis, the fixed bridge was seated(picture 9) and no functional disorders were observed during five months of follow-up.

DISCUSSION.

Alveolar atrophy may present an anatomical limitation to the placement of endosseous implants. Many osseous augmentation techniques, including bone grafting, use of membranes for guided tissue regeneration,8–10 and RWP, have been used in the treatment of this problem. In these treatments, most techniques described placing implants with sufficient bone height (.10 mm) but insufficient width (,4 mm). The following are the benefits of the RWP compared with other methods:

1. the RWP allows the implant to be placed in a less invasive manner and avoids donor-site morbidity caused by bone grafting;
2. the RWP allows primary implant placement and significantly shortens the treatment time;
3. the RWP allows treatment of narrow ridge location within the context of a routine dental office procedure.

The split-crest technique, applied in the present case, was an RWP introduced by joaquim Garcia showed that a preoperative ridge width between 1.5 mm and 3.0 mm had a postoperative ridge width gain between 1 mm and 4 mm after a healing period of six months.

Most RWPs associated with immediate implant placement have used expanded

polytetrafluoroethylene membranes or polyglactin 910 mesh for guided tissue regeneration. Although the possible benefits of guided tissue regeneration have received considerable attention in previous studies, the use of a membrane always increases the risk of complications, such as infections, painful inflamed tissues, and disrupted wound healing. In addition, various studies have reported complication rates of 20% to 50% when using membranes. In RWPs associated with immediate implant placement, the primary wound closure is generally more difficult compared with that of a standard implant placement and the risk of membrane exposure increases because the natural crest is dramatically augmented. For these reasons, we treated five atrophy cases, including the present one, without the membrane technique. Subsequent wound healing and osseointegration of the implants were uneventful. Furthermore, the reason for successful regeneration surrounding the implant without the membrane technique may be attributed to the small size and tapered shape of the expanders, which is a beneficial shape to gradually widen a split crest. Only a small percentage of fusiform defects are made by the splitting process. In a small percentage of defect cases, the membrane is not essential for bone regeneration.

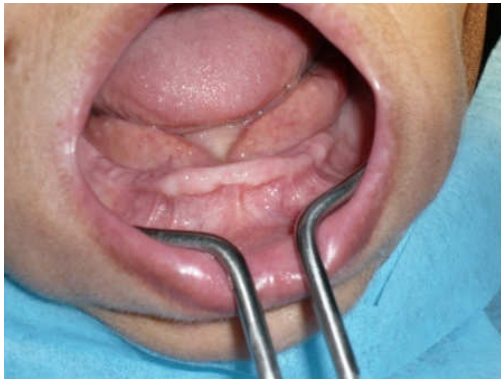REFERENCES.

1. Jensen J, Sindet-Pedersen S, Oliver AJ. **Varying treatment strategies for reconstruction of maxillary atrophy with implant: Results in 98 patients.** J Oral Maxillofac Surg. 1994;52:210–216.
2. De wiji FLJA, Cune MS. **Immediate labial contour restoration for improved esthetic: A radiographic study on bone splitting in anterior single-tooth replacement.** Int J Oral Maxillofac Implant. 1997; 12:686–696.
3. Misch CM, Misch CE. **The repair of localized severe ridge defects for implant placement using mandibular bone grafts.** Implant Dent. 1995;4:261–267.
4. Sindet-Pedersen S, Enemark H. **Reconstruction of alveolar clefts with mandibular or iliac crest bone grafts: A comparative study.** J Oral Maxillofac Surg. 1990;48:554–558.
5. Simion M, Baldoni M, Zaffe D. **Jawbone enlargement using immediate implant placement associated with a splitcrest technique and guided tissue regeneration.** Int J Periodontics Restorative Dent. 1992;12:462–473.
6. Summers R. **The ridge expansion osteotomy (REO).** Compend Contin Educ Dent. 1994;15:422–436.
7. Duncan JM, Westwood M. **Ridge widening for the thin maxilla: A clinical report.** Int J Oral Maxillofac Implants. 1997;12:224–227.
8. Schultz AJ, Gaper AH. **Guided tissue regeneration using absorbable membrane (polyglactin 910) and osseous grafting.** Int J Periodontics Restorative Dent. 1990;10:9–17.
9. Nyman S. **Bone regeneration using the principle of guided tissue regeneration.** J Clin Periodontol. 1991;18:494–498.
10. Nevins M, Mellonig JT. **Enhancement of the damaged edentulous ridge to receive dental implants: A combination of allograft and GORE-TEX membrane.** Int J Periodontics Restorative Dent. 1992;12: 97–111.
11. Rominger JW, Triplett RG. **The use of guided bone regeneration to improve implant osseointegration.** J Oral Maxillofac Surg. 1994;52:106–113.
12. Gotfredsen K, Nimb L, Buser D, et al. **Evaluation of guided bone**

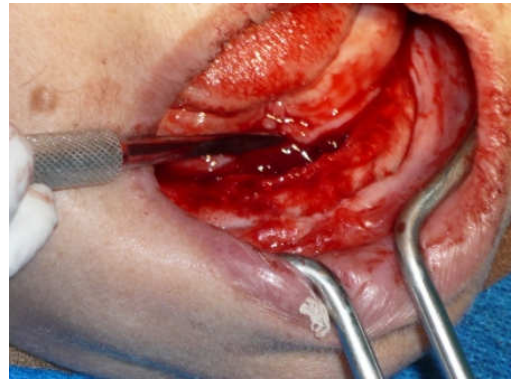
**regeneration's around implants placed into fresh extraction sockets:
An experimental study in dogs.** J Oral Maxillofac Surg. 1993;51: 879–886.

13. Gotfredsen K, Warrer K, Hortin- Hansen E, et al. **Effect of membranes and porous hydroxyapatite on healing in bone defects around titanium dental implants.** Clin Oral Implants Res. 1991;2:172–178.
14. Warrer K, Gotfredsen K, Hortin- Hansen E, et al. **Guided tissue regeneration ensures osseointegration of dental implants placed into extraction sockets.** Clin Oral Implants Res. 1991;2:166–171.
15. Becker W, Becker B, Handelsman M, et al. **Guided bone regeneration for implants placed into extraction sockets: A study in dogs.** J Periodontol. 1991;62: 703–709.

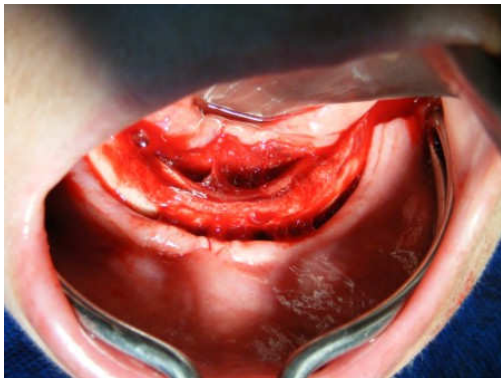Picture 1



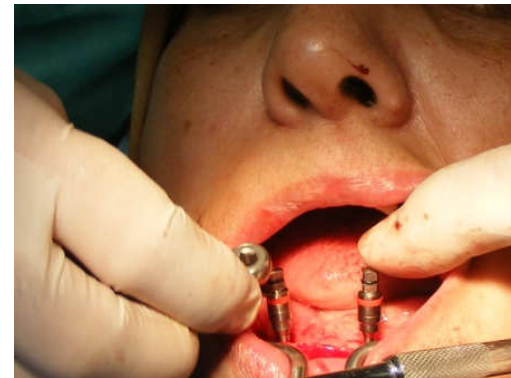Picture 2



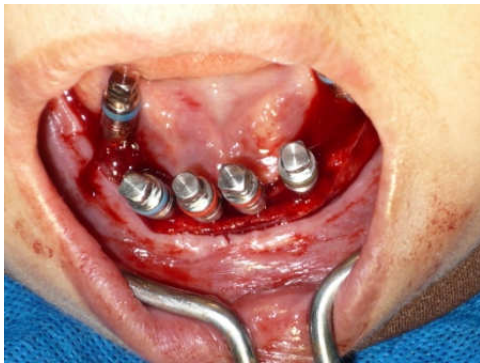Picture 3



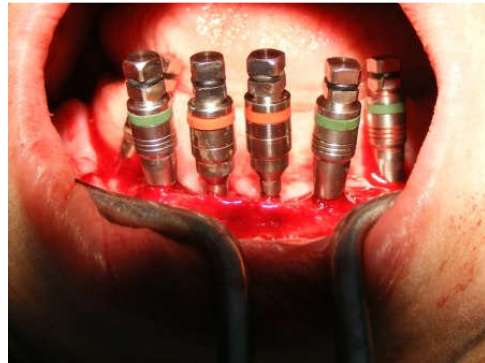Picture 4



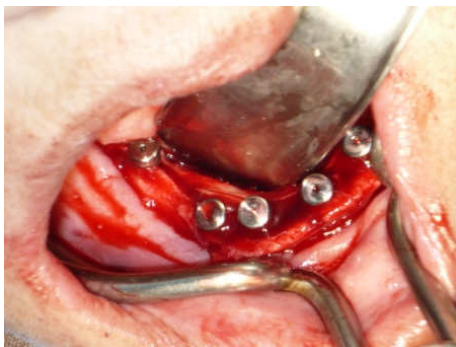Picture 5



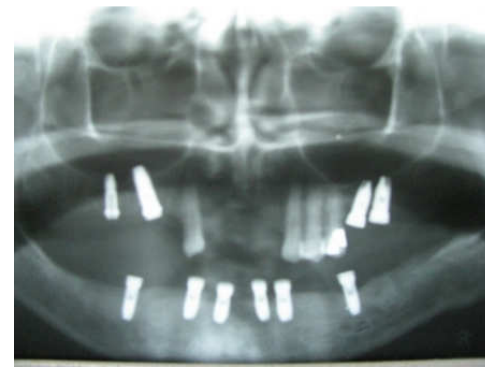Picture 6



Picture 7



Picture 8



Picture 9

